

# **NIR BASED DENTAL IMAGING TECHNIQUES FOR CARIES DETECTION**

**Renee Christina. R<sup>1</sup>, Vanithamani. R<sup>2</sup>**

<sup>1</sup> *Renee Christina. R., PG Scholar, Medical Electronics, Avinashilingam University, Tamilnadu, India* <sup>2</sup> *Mrs.R.Vanithamani, Assistant Professor, Department of Biomedical Instrumentation Engineering, Avinashilingam University, Tamilnadu, India*

## **ABSTRACT**

Demineralization is the common problem that exists these days. Although traditional methods are commonly used to detect them, Near-infrared rays is found to be more beneficial than the other methods. Near-infrared (NIR) is a non-ionizing, minimally invasive approach to detect and quantify caries. In dental imaging, the tooth's optical property exhibits deeper penetration into tooth because of the enamel which is highly transparent to NIR. The first step is using the NIR Light emitting Diode and IR camera the tooth image is acquired. The captured tooth image exhibits a clear variance between the healthy and caries affected region. Since the contrast and resolution of the image captured using IR camera is low, it is enhanced using morphological operation and top-hat transform processing methods. To identify and classify the tooth as caries affected tooth, histogram plot is used. To accurately determine the affected region, the Otsus' segmentation method is used to extract the caries region.

Keywords: Caries, Morphologic operation, Near Infrared, Otsus' method, Segmentation, Tophat transform

## **1. INTRODUCTION**

Conventionally, dental professionals rely mostly on interpretation of caries by dental radiography. Studies based on these methods often show low sensitivity, which means that a large number of lesions may be missed. Sensitivity and specificity are widely used measures to describe and quantify the diagnostic ability of a method. Usual radiograph for the detection of approximal caries in dentine has high specificity (correctly identified healthy surfaces), but the sensitivity (correctly identified surfaces damaged by caries) is highly dependent on the extent of caries damage to the dentine which is due to the greater mineral loss. For enamel caries that lie between adjacent teeth, the sensitivity is low and the lesion size and depth are often underestimated or can even be undetected radio-graphically. Furthermore, failure to detect early caries activity may leave the clinician with no option but restorative treatment rather than reverse or arrest the lesion. Beside the possible hazardous effects of ionizing radiation, there is more possible radiation effect for patient groups such as children and pregnant women [1-3].

At present, caries is a chronic disease in the oral cavity which is common in most countries. It arises mainly due to the demineralization of tooth surfaces by organic acids (originated from the fermentation of carbohydrates by bacteria) and by organic matrix deprivation [3]. This process is vibrant and may be reversed at its early stages [4] if it is detected. The formation of a caries lesion and its development occurs when periods of demineralization are more common than those of remineralization. Thus the disease is categorized by an imbalance between the demineralization and remineralization taking place in enamel. As demineralization process continues, a whitish area appears when the enamel loses the mineral [5]. The mineral loss due to disease development causes visual changes on the tooth surface, starting in a subclinical stage (white spot) and followed by cavitations.

In the study for more precise diagnostic method a non-invasive method for early caries detection based on dental tissue optics is detected. Transillumination (TI) of dental enamel with near-infrared (NIR) light is a new and promising optical imaging technique for detecting the presence of dental caries lesion and measuring its severity. The method is non-destructive, non-ionizing and more sensitive to early demineralization than dental radiography. The boundary between lesion and the surrounding healthy enamel is detected with high contrast difference when illuminated with NIR light. The detected caries can be segmented using an image processing algorithm.

## **2. MATERIALS AND METHODS**

### **2.1 NIR imaging system**

The traditional X-ray method requires dark room procedures and also takes long duration for adjustments and acquiring the image. This NIR system which is developed can overcome these complexities. The NIR imaging system is composed of three unique components, and such as NIR light source, an IR camera to acquire the image, and software for image processing illustrated as in fig.1. The light source consists of a three 950 nm range light emitting diodes which is mounted along with the camera for maximum illumination on the tooth. The NIR LED used here is Infrared T-1¼ LED 950nm 50° LD271. The features of LD271 are GaAs -LED in

5mm radial package (T 1 3/4), typical peak wavelength 950nm, high reliability and its forward voltage is 1.30 – 1.90v.

The camera plays a very crucial role in the caries detection system. The camera used in this system requires a standard procedure to make it as an IR camera. This is achieved by converting a Charge-Coupled Device camera to IR camera by replacing the original infra red filter with another filter which allows infrared. To capture the tooth caries image the light source must be focused on appropriate location and the image is captured and stored in a computer for further processing. The camera is controlled by the computer to which it is connected and the magnification can be controlled by adjusting the lens to focus on the caries. The image is processed using the MATLAB in the computer. The selection criteria of the camera are based on the following aspects. The response of image sensor of camera should lie in the Near Infra-Red region (950nm). The features of the camera used in this work are it has a CMOS sensor with a resolution of 640x480 pixels, a 16-bit colour still image can be captured and the cost is very-low compared to industrial IR Cameras.

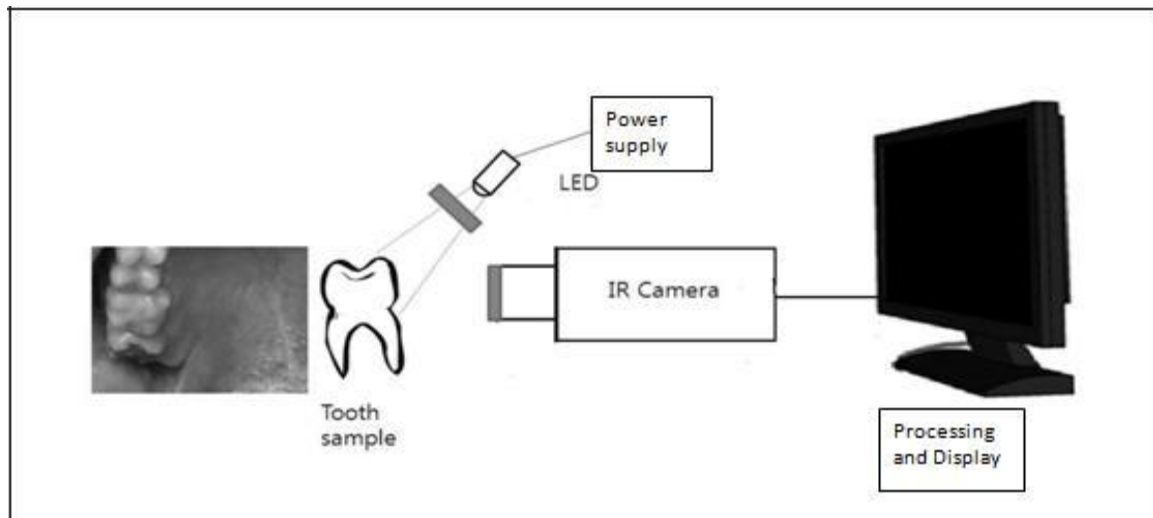


Fig.1. NIR System

## 2.2 NIR image acquisition

The procedure to acquire the NIR image is to adjust the distance between the tooth and the light source. It should be such that there is maximum illumination on the site of affected area of the tooth. The camera focus is adjusted such that a clear image is visible on the display. The image is captured once the image of tooth is clearly visible. Finally the image captured is processed using MATLAB for image analysis using histogram plot and segmentation is performed after morphological operation.

## 3. IMAGE ANALYSIS

### 3.1 Obtaining Histogram of the image

A collection of tooth images are taken for analysis. The areas that are to be analyzed are extracted for all the images. They are then resized to square images. The square images are then converted to gray scale images. The histograms of these images are taken and a thorough analysis is made. Depending upon the concentration of pixel intensities in different ranges, we classify them into caries affected or not.

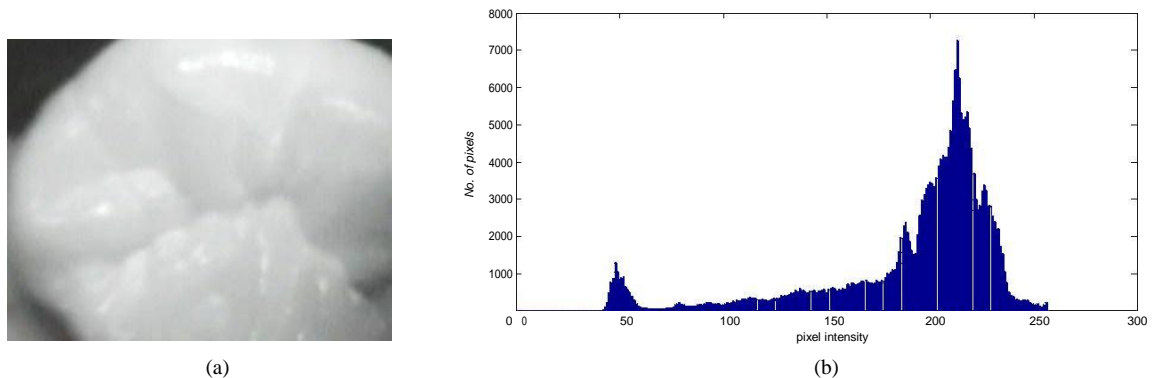


Fig.2. (a) Normal NIR tooth image (b) Normal NIR tooth image histogram plot

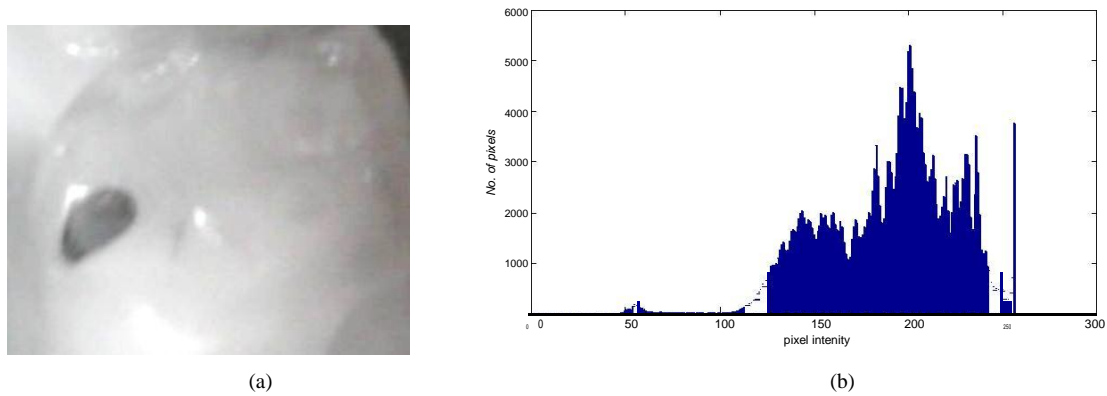


Fig.3. (a) Caries affected NIR tooth image (b) Caries affected NIR tooth image histogram plot

#### 4. IMAGE SEGMENTATION

##### 4.1 Morphological operation

The image captured from the IR camera is of low contrast and resolution and it requires a pre-processing. The morphological operation, white top hat transform is used for the image enhancement. The segmentation is performed using Otsus' method. In which the Otsus' method was found effective in caries detection

To identify possible infestation sites among small spots segmented from the binary image, a morphological filtering approach is employed, which can eliminate or maintain the spots on the image according to their area size by the procedure of erosion and dilation. The erosion procedure shrinks the spots, so that a spot will be eliminated if it is smaller than a certain size. The dilation procedure is then performed to expand the spots remaining after the erosion process to their original size. After this the segmentation can be performed using the threshold method.

##### 4.2 Threshold Selection based on Otsu's method:

The enhanced tooth image is segmented using the Otsus' method. The Otsus' method is a global thresholding selection method, which is widely used because of its simplicity and effectiveness [6, 7]. In Otsu's method, it exhaustively searches for the threshold that minimizes the intra-class variance, defined as a weighted sum of variances of the two classes:

$$\sigma_w^2 = \omega_1^2 \sigma_1^2 + \omega_2^2 \sigma_2^2 \quad (1)$$

Weights  $\omega_1$  and  $\omega_2$  are the probabilities of the two classes separated by a threshold  $t$ .  $\sigma_1^2$  and  $\sigma_2^2$  are variances of these classes. Otsu method shows that minimizing the intra-class variance is the same as maximizing inter-class

variance which is expressed in terms of class probabilities  $\omega_1$

and class means  $\mu_1$ .

$$\sigma_b^2 = \omega_1^2 \mu_1^2 + \omega_2^2 \mu_2^2 - (\omega_1 \mu_1 + \omega_2 \mu_2)^2 \quad (2)$$

By this the caries affected region can be separated from the other region of the tooth.

#### 5. RESULTS AND DISCUSSION

The experiments were conducted on sample teeth with caries. Images were captured using proposed NIR dental imaging system. Captured images are processed using MATLAB. The tooth is classified as caries affected by the histogram plot.

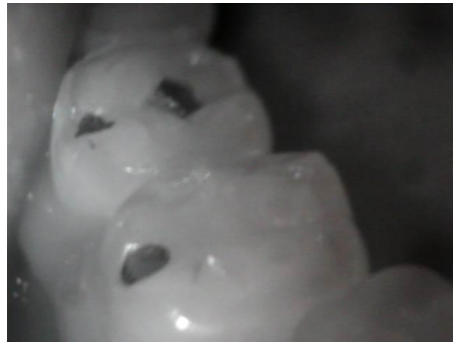##### 5.1 Histogram of a Normal Tooth

The figures 2a and 2b show the NIR image of a normal tooth and its corresponding histogram. The histogram of a normal tooth shows that the pixel intensity is centered on the 200 to 250 range and the peak value of the number of pixels lies in this range. This indicates the presence of more number of white pixels for a normal tooth. And it is also found that the numbers of black pixels are very minimal.

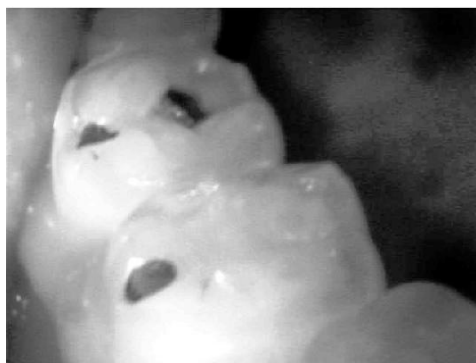##### 5.2 Histogram of Early stage of Caries

The figures 3a and 3b show the NIR image of a caries tooth and its corresponding histogram. The histogram of caries affected tooth shows that the pixel intensity is centered on the 100 to 175 range and the peak value of the number of pixels lies in this range. The histogram of the tooth in its severe stage of decay shows that the pixel intensity is centered on the 0 to 150 range and the peak value of the number of pixels lies in this range. The pixel intensities are distributed widely which depicts the presence of severe caries.

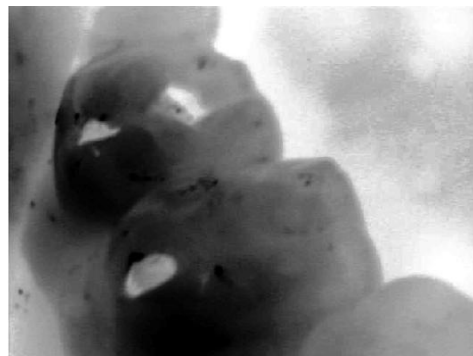The caries affected teeth are preprocessed using Morphological operations. The preprocessed images are segmented using Otsus' segmentation methods. Otsus' threshold method is found to be successful in detecting the caries region in most of the resulting images.



(a) Occlusal tooth image-1 captured by proposed NIR system



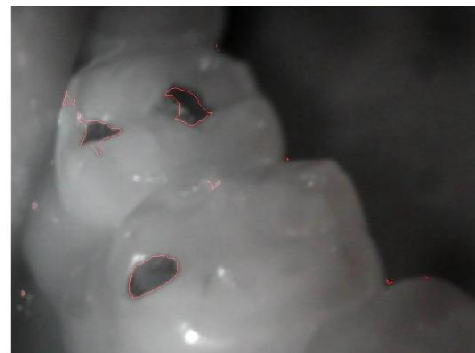(b) Enhancement of the input image



(c) Inverted image

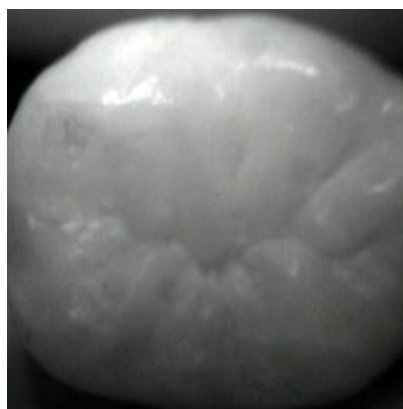

(f) Otsus' segmentation method



(g) Segmented region over the input image

Fig.4. Experimental Results 1- occlusal tooth image



(a) Occlusal tooth image 2 captured by proposed NIR system

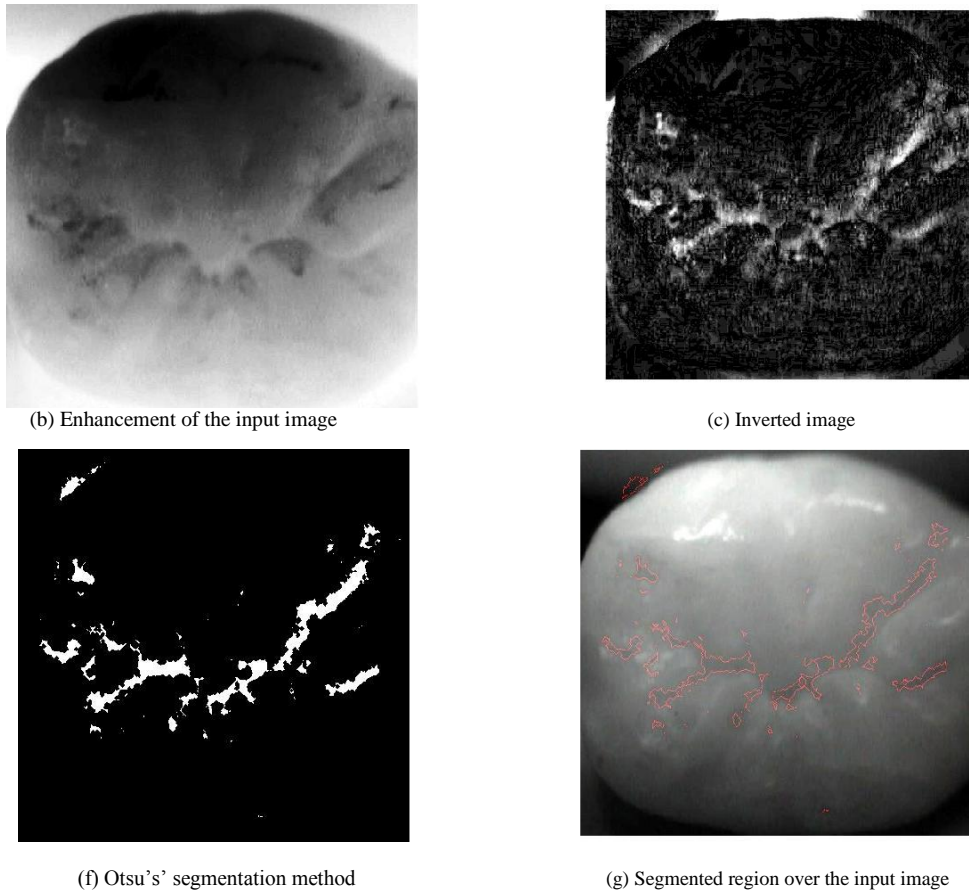
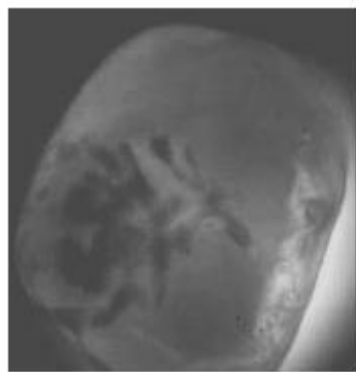
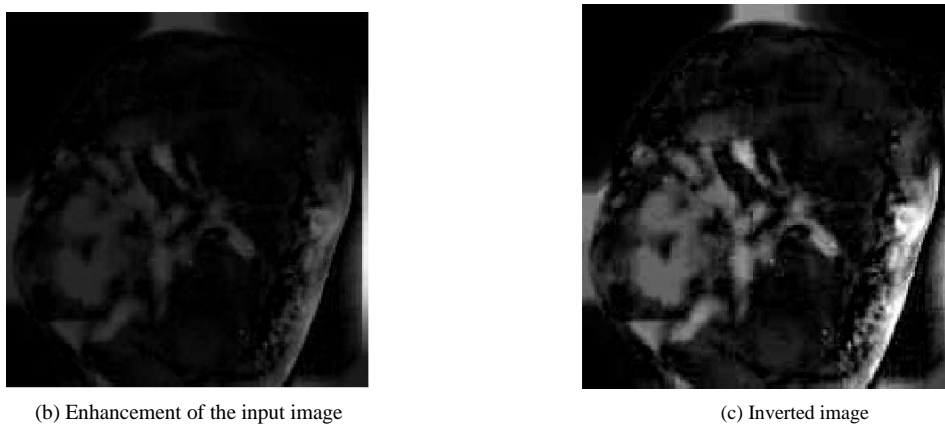


Fig.5. Experimental Results 2 - occlusal tooth image

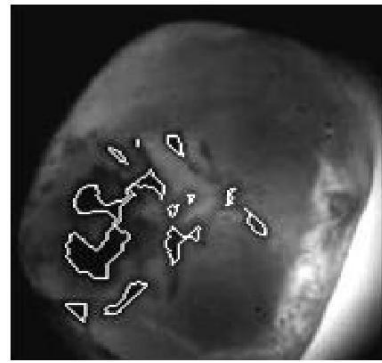


(a) Occlusal tooth image captured by proposed NIR system



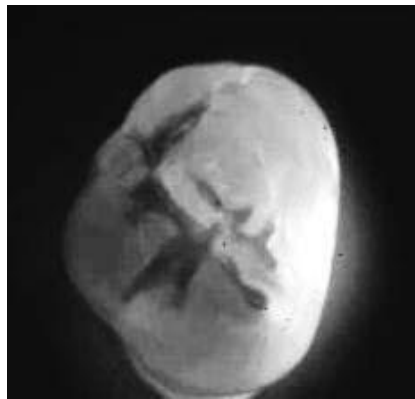

(f) Otsu's' segmentation method

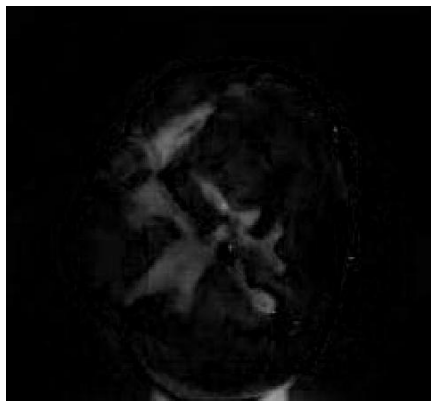


(g) Segmented region over the input image

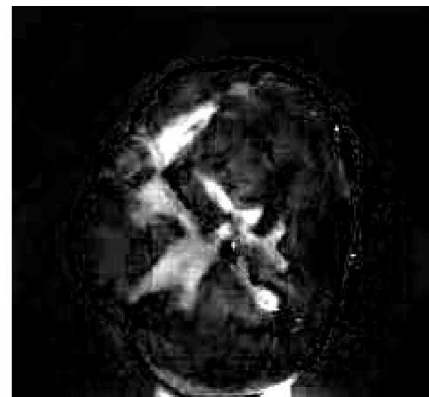
Fig.6. Experimental Result 3- occlusal tooth image




(a) Occlusal tooth image captured by proposed NIR system



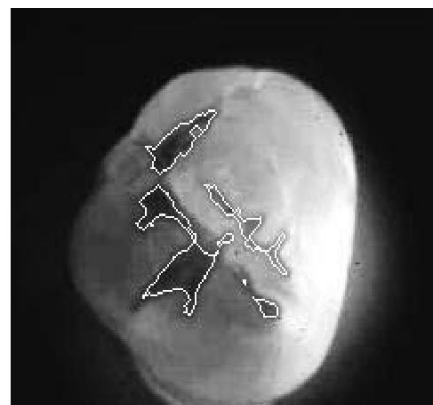(b) Enhancement of the input image



(c) the inverted image

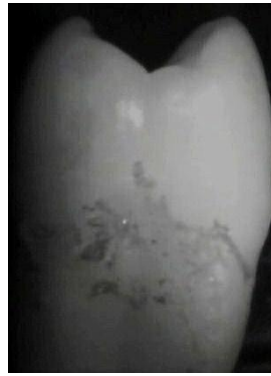

(f) Otsu's' segmentation method

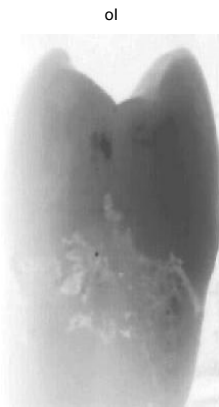

(g) Segmented region over the input image

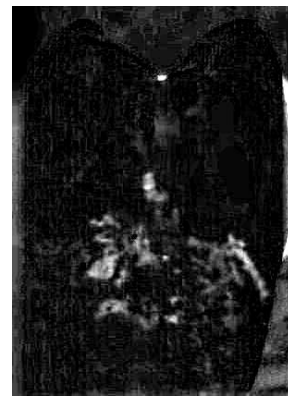Fig.7. Experimental Result- occlusal tooth image



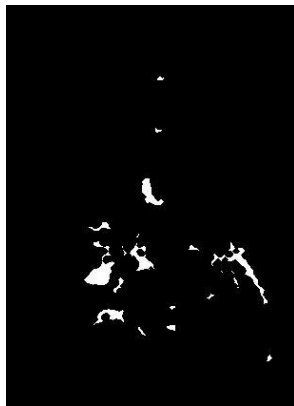
(a) Occlusal tooth image captured by proposed NIR system



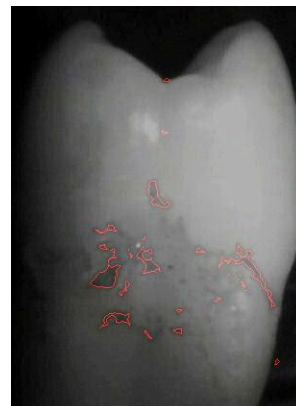(b) Enhancement of the input image



(c) Inverted image



(f) Otsu's segmentation method



(g) Segmented region over the input image

Fig.8. Experimental Result 4 of occlusal tooth

## **6. CONCLUSION**

The proposed system has three main stages that are the placement of NIR, capturing of image by IR camera and processing of acquired images using MATLAB. It is also user friendly and low cost than the traditional X-rays. Previous works regarding caries detection has intentionally been limited. Only some basic algorithms for image enhancement and segmentation have been developed. This work uses the local thresholding algorithm Otsus' in the development of method for segmentation of caries lesions.

## **REFERENCES**

1. R. Hibst and R. Gall, "Development of a diode laser-based fluorescence caries detector," *Caries Research*, vol. 32, no. 4, article 294, 1998.
2. Schneiderman, M. Elbaum, T. Shultz, S. Keem, M. Greenebaum, and J. Driller, "Assessment of dental caries with digital imaging fiber-optic transillumination (DIFOTITM): in vitro Study," *Caries Research*, vol. 31, no. 2, pp. 103–110, 1997.
3. L. Darling and D. Fried, "Optical roperties of natural caries lesions in dental enamel at 1310-nm," in *Lasers in Dentistry XI*, P. Rechmann and D. Fried, Eds., vol. 5687 of *Proceeding of SPIE*, pp. 102–110, San Jose, Calif, USA, January 2005.
4. Nakornchai S, Atsawasuwab P, Kitamurac E, Suraritd R, Yamauchi M. "Partial biochemical characterisation of collagen in carious dentin of human primary teeth". *Arch Oral Biol* 2004; Vol49:pp267-273.
5. Núñez DP, Bacallao LG. Bioquímica de la "caries dental". *Rev Haban Cienc Méd* 2012; Vol9:pp156-166.
6. N. Otsu, "A Threshold Selection Method from Gray-Level Histogram", *IEEE Trans. Systems Man, and Cybernetics*, Vol. 9, pp. 62-66, 1979
7. Jackway, P.T. Improved morphological top-hat, *Electronics Letters*, Vol: 36(14), 2000, pp: 1194-1195